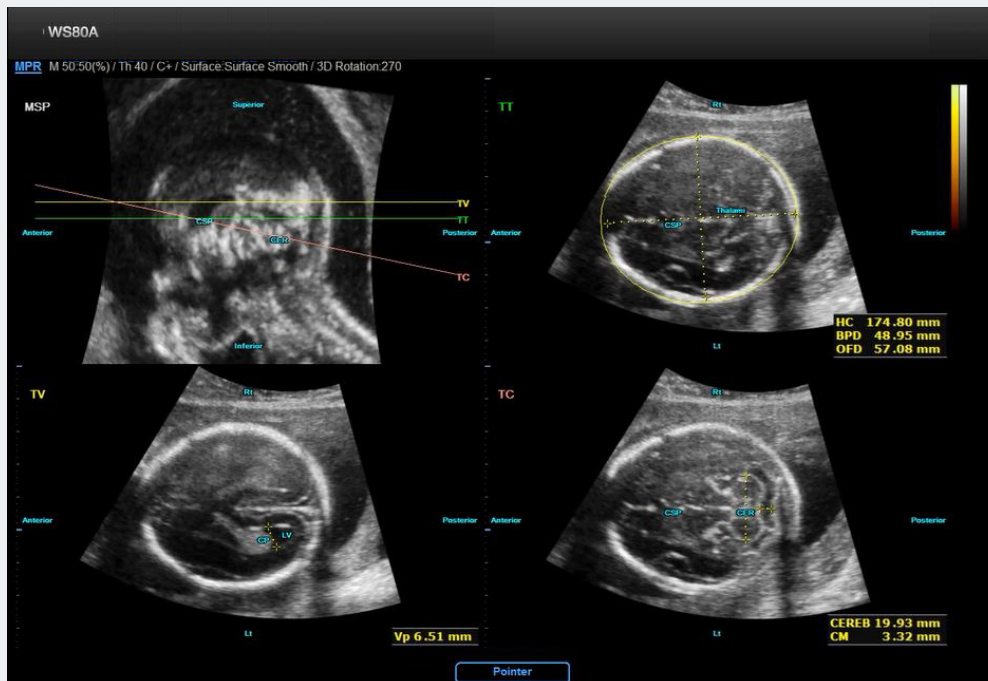


## WS80A with Elite

# A novel semi-automatic method for biometric measurements of the fetal brain

*KwangHee Lee, Junsang Yoo, Sungyoon Kim.*

*Infrastructure Technology Lab, R&D Center, Samsung Medison, Seoul, Korea*

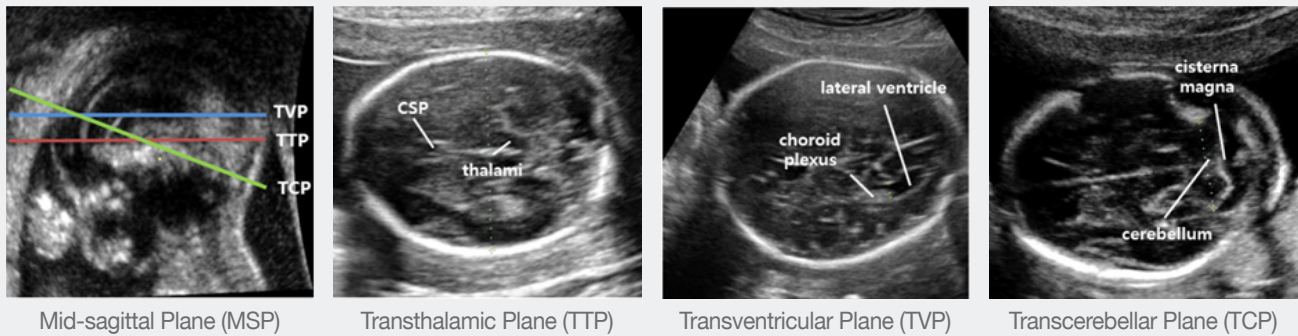


*"5D CNS has three advantages; 1) high success rate of over 90% was obtained under clinical evaluation, 2) number of operations is significantly reduced to about 85%, and 3) examination time is remarkably shortened to about 90% (20 seconds)."*

## Introduction

Ultrasound has been used as the main modality for diagnosis of fetal central nervous system (CNS). During late first, second and third trimesters of gestation in low risk pregnancies, fetal CNS anomalies have been diagnosed by the combination of recognizable markers such as the lateral ventricles, the cerebellum and cisterna magna, and the cavum septi pellucidi (CSP). In addition, the biparietal diameter (BPD), the occipitofrontal diameter (OFD) and the head circumference (HC) not only are commonly used for assessing fetal age and growth, but also may be useful to identify some cerebral anomalies<sup>1</sup>. Effective markers for the diagnosis of such abnormalities must be measured and assessed in three standardized views of the fetal head such as the transventricular (TV) plane, the transcerebellar (TC) plane and the transthalamic (TT) plane. In this paper, we present a semi-automatic method specialized for extracting three standard scanning planes from 3-D ultrasound scan of fetal brain.

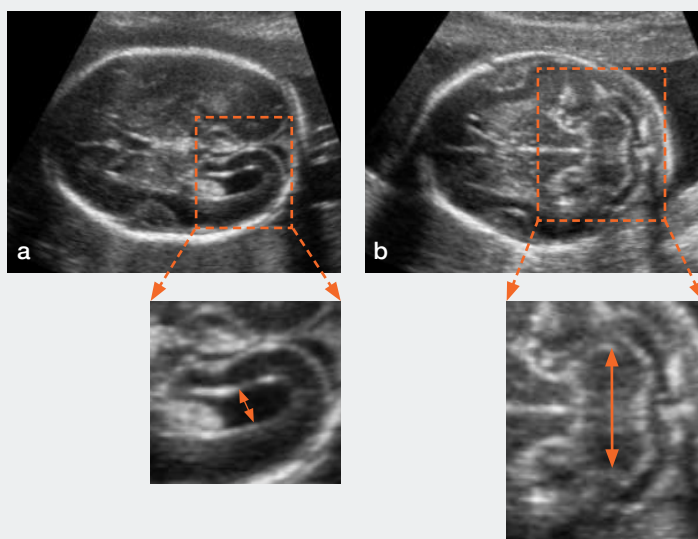
5D CNS receives volume data acquired with 3-D ultrasound of fetal head and manually selected two initial reference points (IRPs) as inputs, and extracts the three standard axial planes which are commonly referred to as the transthalamic (TT) plane, the transventricular (TV) plane and the transcerebellar (TC) plane. After the standard scanning planes are extracted, the measurements in each plane are automatically obtained and major landmarks are annotated. The orientation legends (Superior, Inferior, Anterior, Posterior, Lt, Rt) are displayed as well.



**Figure 1.** The mid-sagittal plane and the three standardized axial planes of the fetus.

## Technology

In order to make the problem tractable with high accuracy, we reduce the dimension of the search space using relative anatomical relations between the initial axial plane and the standardized planes based on the initial reference points (IRPs). To extract the three standardized planes, we exploit a pattern classification algorithms on the initial axial plane with IRPs. However, since our algorithms consider only anatomical appearance of reference images, it is difficult to extract true standardized planes that perfectly correlate with biometric measurement protocol of the International Society of Ultrasound in Obstetrics and Gynecology (ISUOG). Thus, we combine clinical knowledge-based cues with our pattern classification algorithms to determine the best standardized planes that are clinically significant (Figure 2, 3).



**Figure 2.** Clinical significance

- (a) In TVP, the widest part of lateral ventricle with strong ventricle wall should be measured.
- (b) TCP should pass through the center of the cerebellum and widest part should be measured.

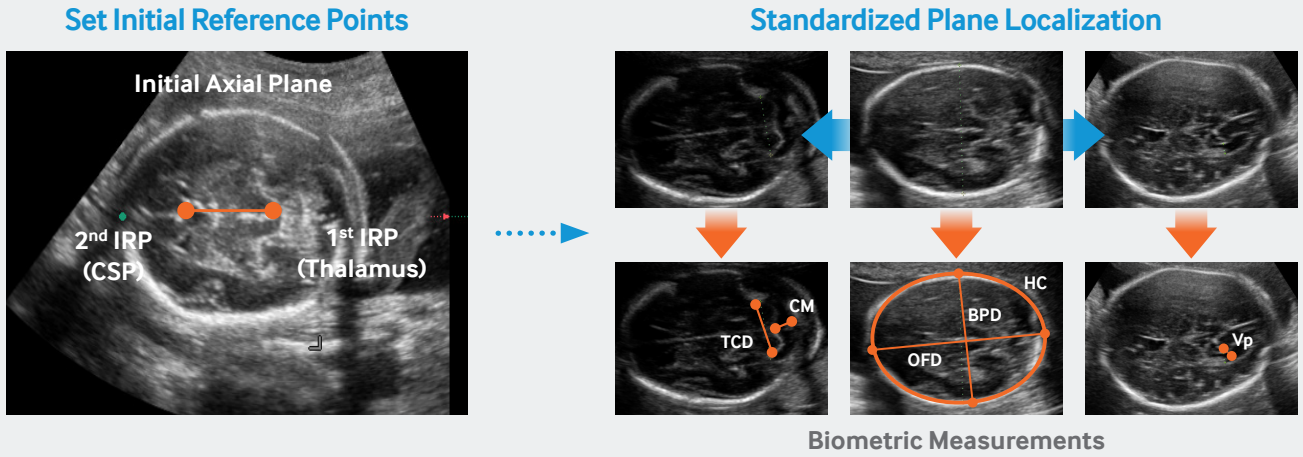


Figure 3. The workflow of our algorithm

### Performance

43 volume data acquired from fetuses between 20+0 to 28+0 weeks of gestational age have been used to investigate the robustness and the accuracy of 5D CNS. Figure 4 shows the success rates for the MSP and three standardized planes (TT planes, TV planes, TC planes). We tested with the pattern classification algorithms.

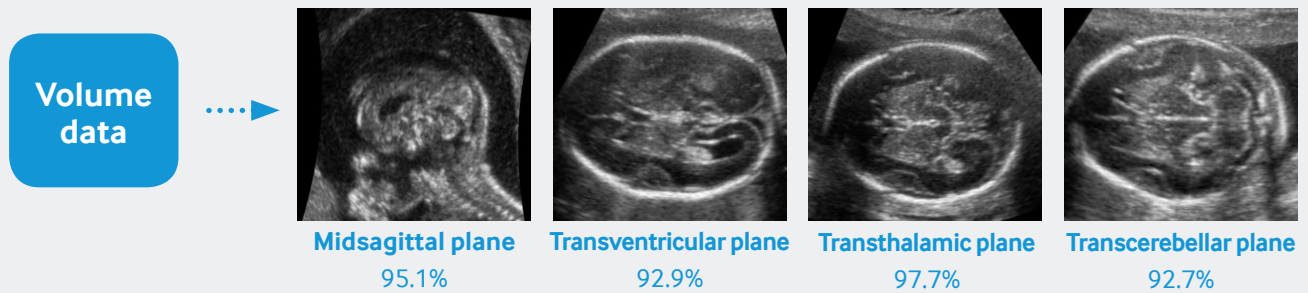


Figure 4. Success rates for MSP and three axial planes

Figure 5 shows the success rates and measurement errors for the six biometric measurements. The experts evaluated success or failure by confirming whether calipers were correctly placed in accordance with biometric-measurement protocol. Table 1 shows the number of operations and running time for manual and automatic biometric measurements. The number of operations is considerably reduced from 13 to 2 compared to manual measurement. As a result, the examination including scanning time is also remarkably decreased from several minutes to about 20 seconds.

	TTP			TVP	TCP		Total	Time
	HC	BPD	OFD	TV	TCD	CM		
Manual	3	2	2	2	2	2	13	5min
Automatic	The Initial reference points						2	5sec

Table 1. The number of operations and the running time.

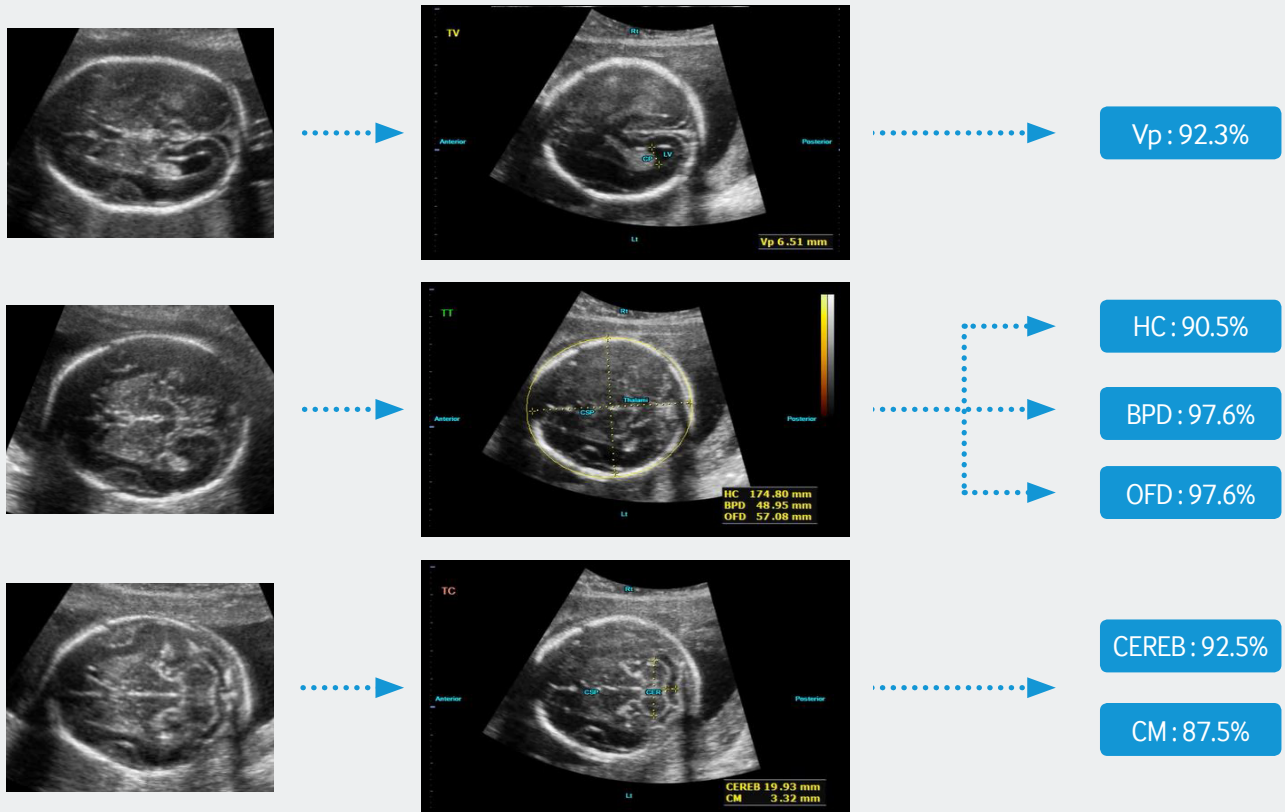


Figure 5. Success rates of six biometric measurements.

## Conclusion

We proposed a novel semi-automatic method for biometric measurements of the fetal CNS from 3D ultrasound brain volume data. Our main contributions are as follows:

- We dramatically reduce the search space through anatomical relations between the MSP and the standardized planes.
- We extract the optimal standardized plane with clinical significance by combining pattern classification algorithm and the clinical knowledge-based cues that consider not only anatomical appearance but also the ISUOG guideline.

### The proposed method has three advantages.

- High success rate of over 90% was obtained under clinical evaluation.
- Number of operations is significantly reduced to about 85% (from 13 to 2).
- Examination time is remarkably shortened to about 90% (from 5 minutes to 20 seconds).

### Supported Systems

(1) WS80A with Elite

### References

- (1) Sonographic examination of the fetal central nervous system: guidelines for performing the basic examination and the fetal neurosonogram. *Ultrasound in Obstetrics and Gynecology*, 29:109–116 (2007)
- (2) Ja-young Kwon. When US meets 5D: Fetal long bone and brain. *World Congress on Ultrasound in Obstetrics and Gynecology* (2014)